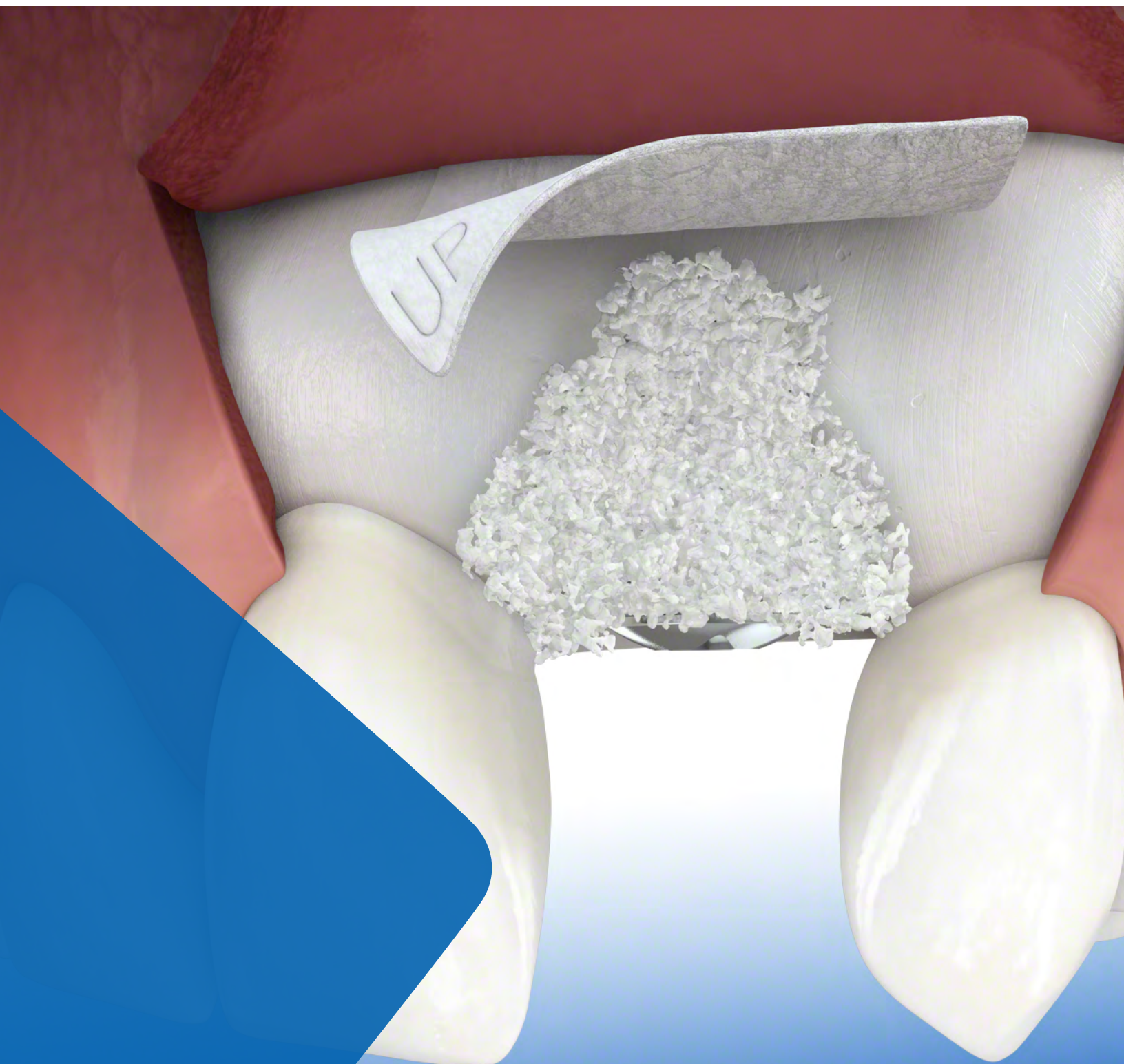

Minor Bone Augmentation



Overview

Guided bone regeneration utilizing bone grafting materials and barrier membranes result in stimulating and directing the growth of new bone. Autologous bone and/or a biomaterial is placed into the defect and then a barrier membrane is applied on top of the graft to assist in wound-healing and prevent the ingrowth of soft-tissue.

Although effective in stimulating new bone formation, the resorption rate of an autologous bone graft is substantial over time. Due to their unique properties, Geistlich biomaterials bone substitutes offer a viable alternative by providing a stable scaffold for new bone formation and maintaining long-term volume preservation due to their low resorption rate.

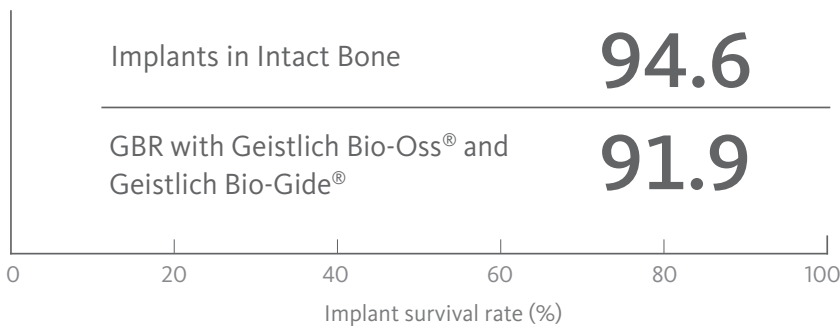
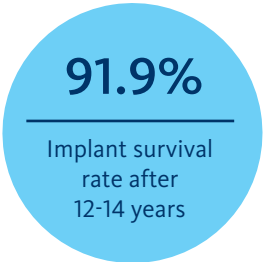
The use of Geistlich Bio-Gide® in conjunction with a bone substitute provides undisturbed and significantly enhanced bone regeneration.^{1,2} Geistlich biomaterials can be used successfully in cases with fenestration or dehiscence defects around implants.

Advantages of Utilizing Geistlich Biomaterials in Guided Bone Regeneration Procedures

- › Undisturbed bone regeneration^{1,2}
- › Reliable bone formation³⁻⁸
- › Excellent osseointegration and long-term volume preservation^{5,9,10}
- › Long-term implant survival rate¹¹
- › Complication-free healing¹²
- › Excellent esthetic outcomes¹³
- › The extent of any future invasive surgery can be reduced

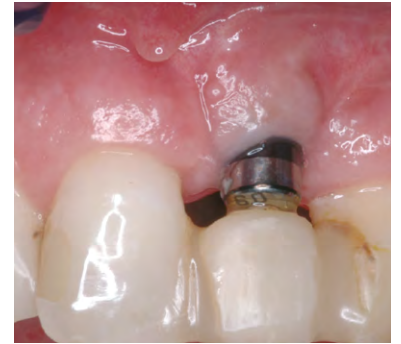Numerous Studies Prove Excellent Long-Term and Stable Esthetic Results

After 12–14 years implants that were placed in bone augmented with Geistlich Bio-Oss® and Geistlich Bio-Gide® show the same survival rate as implants in native bone.¹¹

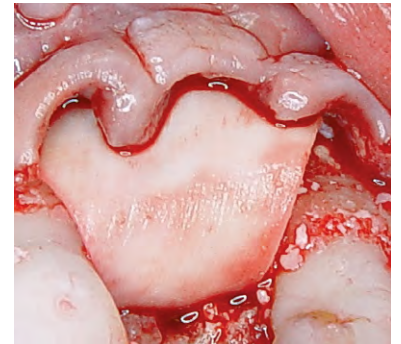


Predictable Results

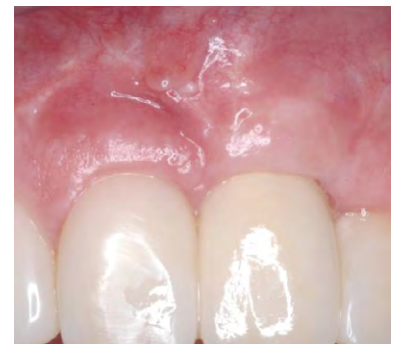Excellent preservation of facial bone wall at 5 years.⁴



Implant treatment with no graft placement (peri-implant defect)



Contour augmentation of peri-implant defect after prior decontamination of the implant surface with Geistlich biomaterials



5 year result with good hard and soft-tissue contour

Case courtesy of: Prof. Dr. Anton Sculean Berne, Switzerland

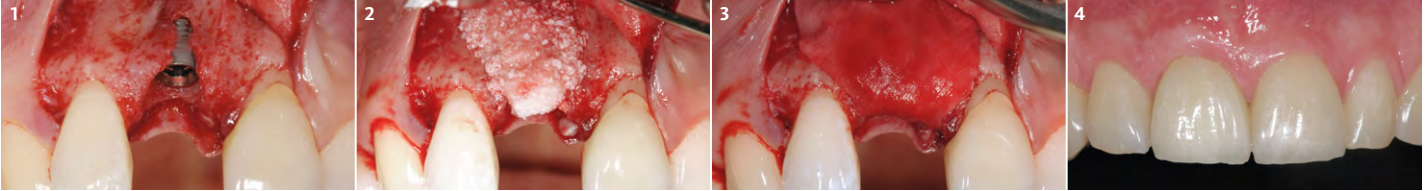
Case Documentation

▶ Peri-Implant Defects with Minor Bone Augmentation

Dr. Ronald Jung, Zurich, Switzerland

Objectives

- > Correct peri-implant defects in the esthetic zone
- > Build buccal bone volume
- > Mimic natural root prominence
- > Support the peri-implant tissue to yield an optimally constructed contour
- > Achieve long-term optimal esthetic results



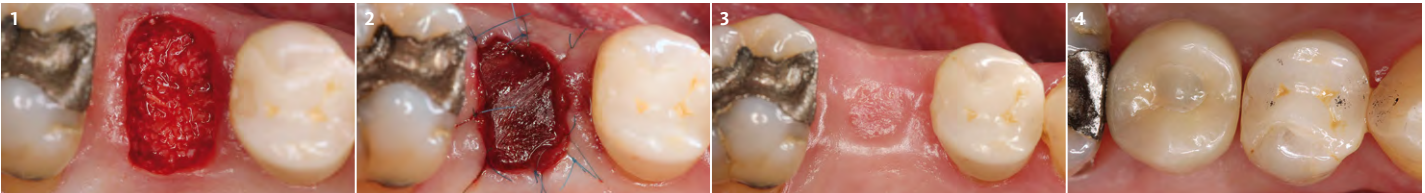
- 1 After implant placement a bone dehiscence associated with a one wall defect is observed in region 8.
- 2 Geistlich Bio-Oss Collagen® is carefully applied. Geistlich Bio-Oss® granules are used in addition to round the edge.
- 3 The defect is covered with Geistlich Bio-Gide®.
- 4 At 10 months: optimal ridge contour is achieved.

▶ Dehiscence Defects Around Implants

Prof. Dr. Daniel Buser, Berne, Switzerland

Objectives

- > Obtain soft-tissue healing over 4–8 weeks, in order to achieve an intact soft-tissue covering
- > Obtain the correct 3D position of the implant during and after implant placement
- > Local contour augmentation in the facial region with autologous bone chips, Geistlich Bio-Oss® granules and Geistlich Bio-Gide®
- > Primary wound closure with 6–8 week healing phase
- > Esthetic restoration with screw-retained implant crown



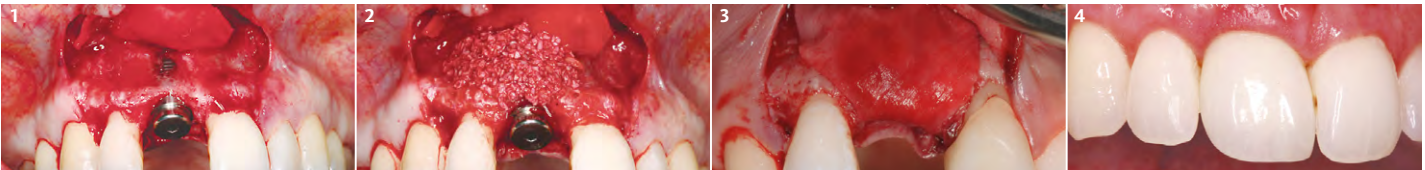
- 1 Defect filled with autologous bone.
- 2 Contour augmentation is achieved with Geistlich Bio-Oss®.
- 3 The augmentation material is covered with Geistlich Bio-Gide® applied with a double-layer technique.
- 4 An optimal esthetic outcome and stable tissue height at 5 year follow-up.

▶ Minor Bone Augmentation

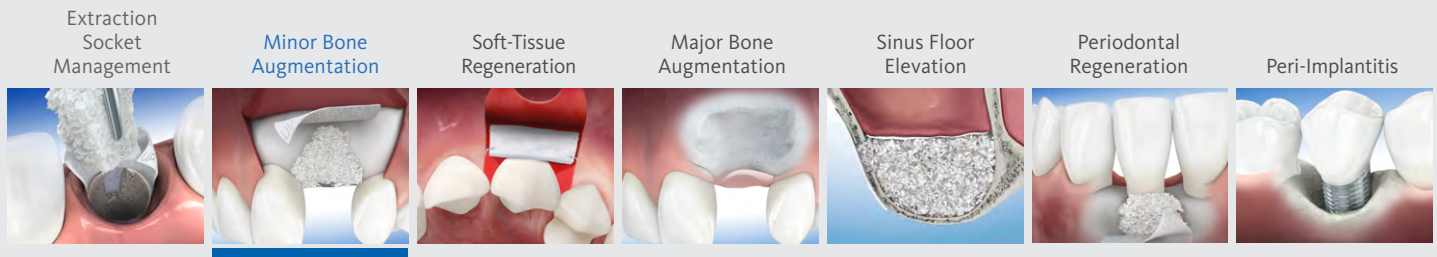
Prof. K. L. Achermann, Filderstad, Germany

Objectives

- > Esthetic restoration of tooth #8
- > After implant placement the fenestration defect is treated with Geistlich Bio-Oss® granules and Geistlich Bio-Gide®
- > Obtain functional and esthetic restoration



- 1 Bone loss showing apical implant threads.
- 2 Application of Geistlich Bio-Oss®.
- 3 Application of Geistlich Bio-Gide®.
- 4 Good healing of the hard and soft-tissue 13 months after surgery.



Therapeutic Areas

At Geistlich Biomaterials, we are committed to developing treatments that are uniquely matched to the clinical situations you see every day. That's why we do more than bring you a family of products – we provide proven solutions in specific therapeutic areas.

The recommended Geistlich products below are the ideal biomaterials for use in **Minor Bone Augmentation** procedures.

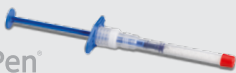Recommended Products for Minor Bone Augmentation

BONE SUBSTITUTES

Geistlich
Bio-Oss®



Geistlich
Bio-Oss Pen®



Geistlich
Bio-OssCollagen®



MEMBRANES

Geistlich
Bio-Gide®



COMBINATION

Geistlich
Combi-Kit Collagen



The Ideal Geistlich Biomaterials for Minor Bone Augmentation

When used in combination, these proven and reliable products provide a foundation for long-term clinical success in regenerative dentistry.

Geistlich Bio-Oss® provides a stable scaffold for bone formation leading to long-term volume preservation, while Geistlich Bio-Gide® ensures undisturbed bone regeneration and prevents soft-tissue ingrowth.

For additional information about Minor Bone Augmentation, please visit the Dental Professional section of our website: www.geistlich-na.com

CAUTION: Federal law restricts these devices to sale by or on the order of a dentist or physician.

For information on indications, contraindications, precautions, and directions for use, please refer to the Geistlich Bio-Oss®, Geistlich Bio-Oss Collagen® and Geistlich Bio-Gide® Instructions for Use at: www.geistlich-na.com/ifu

Geistlich Pharma North America, Inc.
202 Carnegie Center
Princeton, NJ 08540
Customer Care Toll-free: 855-799-5500
info@geistlich-na.com
www.geistlich-na.com

- 1 Perelman-Karmon, M. et al. (2013) Int J Periodontics Restorative Dent. 32(4): 459-65.
- 2 Wallace, S.S. et al. (2005) Int J Periodontics Restorative Dent. 25(6): 551-59.
- 3 Aghaloo, T.L. et al. (2007) Int J Oral Maxillofac Implants. 22 Suppl: 49-70.
- 4 Orsini, G. et al. (2005) J Biomed Mater Res B Appl Biomater. 74(1): 448-57.
- 5 Piattelli, M. et al. (1999) Int J Oral Maxillofac Implants. 14(6): 835-40.
- 6 Orsini, G. et al. (2007) Oral Dis. 13(6): 586-93.
- 7 Traini, T. et al. (2007) J Periodontol. 78(5): 955-61.
- 8 Degidi, M. et al. (2009) Clin Implant Dent Relat Res. 11(3): 178-82.
- 9 Sartori, S. et al. (2003) Clin Implants Res. 14(3): 369-72.
- 10 Maiorana, C. et al. (2005) Int J Periodontics Restorative Dent. 25(1): 1925.
- 11 Jung, R.E. et al. (2013) Clin Oral Implants Res. 24(10): 1065-73.
- 12 Becker, J. et al. (2009) Clin Oral Implants Res. 20(7): 742-93.
- 13 Buser, D. et al. (2011) J Periodontol. 82(3): 342-49.